

UNIVERSITY OF SIENA
School of Dental Medicine
Dean Office

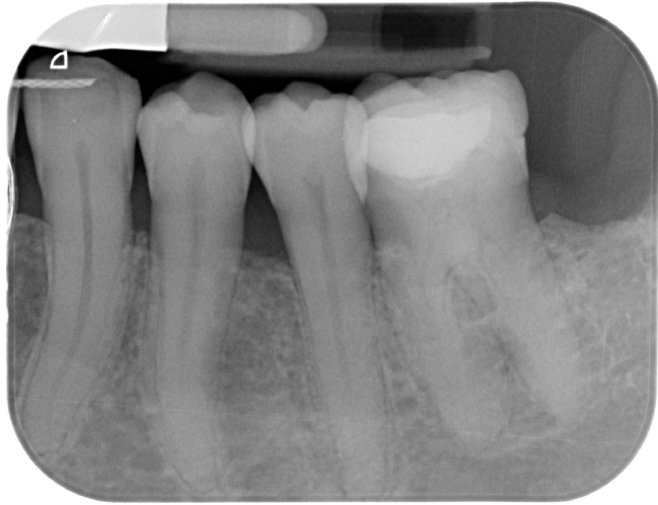- **Caliform as intermediary medication in the treatment of roots with periapical lesion.**
- **Denise IK Pontoriero, Marco Ferrari**
- **University of Siena-Italy**



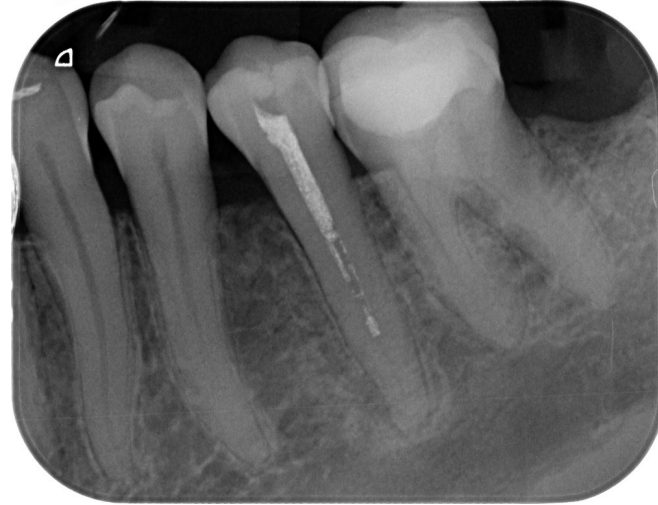Caliform as intermediary medication in the treatment of roots with periapical lesion.

- **Abstract:** This study aimed to collect long-term restorative and endodontic outcomes of endodontically treated teeth (ETT). Methods: Necrotic teeth with periapical lesions were included in the study and were recalled up to 15 years with a median of 8.5 years. The most frequently used obturation techniques were warm gutta-percha Continuous Wave of Condensation in 75% of cases, and Carrier-Based in 25%. A total of 70 teeth were included in the study, of which, 15 were premolars (20%), 35 molars (50%), and 20 anterior teeth (30%, II e V sextant); 40 ETT belonged to the mandible and 30 to maxillae. At baseline, 66 sample teeth (66%) showed symptoms (tenderness/pain to percussion) and 34 (34%) had periapical radiolucency. In all these teeth an intermediary medication was made using Caliform (Ogna), a special formulation of calcium hydroxide ready to be used. The intermediary medication was kept for around 2-3 weeks before the final obturation. After being endodontically treated, ETT were restored by direct or indirect restorations, and in 45 of them, posts were luted. Regarding the quality of root filling, 55 teeth showed good fillings (gutta-percha at the radiologic apex), 15 long fillings (longer than 1 mm of the radiographic apex), and no root was filled shortly (shorter than 1 mm from the radiographic apex). At the recall, 67 ETT showed good coronal margin, 2 not-so-good margins (margin wasn't feeling precise with the sharp explorer), and 1 clear opening of the margins radiographically. Success was recorded in 66 ETT, 1 showed irreversible failure and 3 reversible complications. One ETT failed because of a root fracture. Two ETT showed non-irreversible periodontal complications and the last prosthodontic complications. Accordingly, with Kaplan–Meier analysis, the survival rate after 15 years was 97% (Interval of Confidence (IC) 95.1– 98.3). Conclusions: The use of an intermediary medication with a calcium hydroxide paste, an accurate cleaning of root canals, a correct filling (at the apex) of root combined with proper coronal margins allow obtaining a long-term high success rate in necrotic teeth with a periapical lesion at the baseline.

MAY 2022



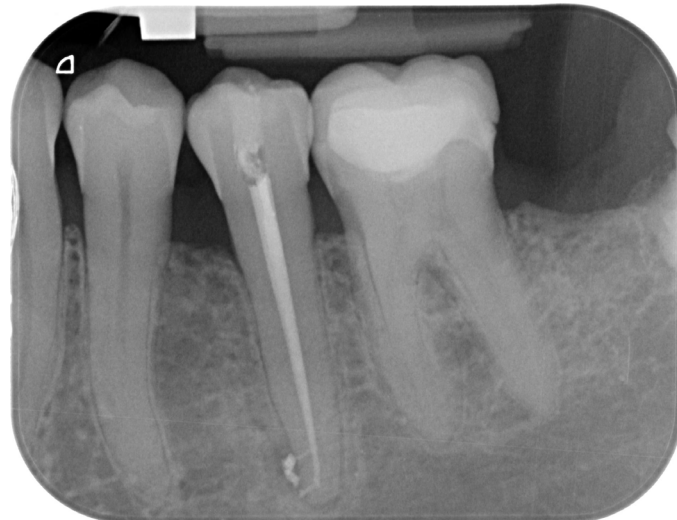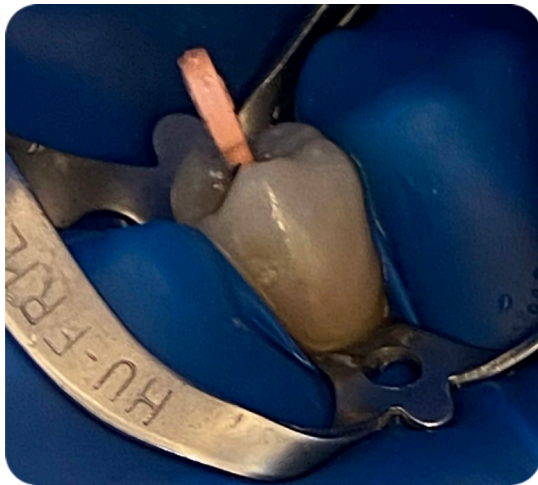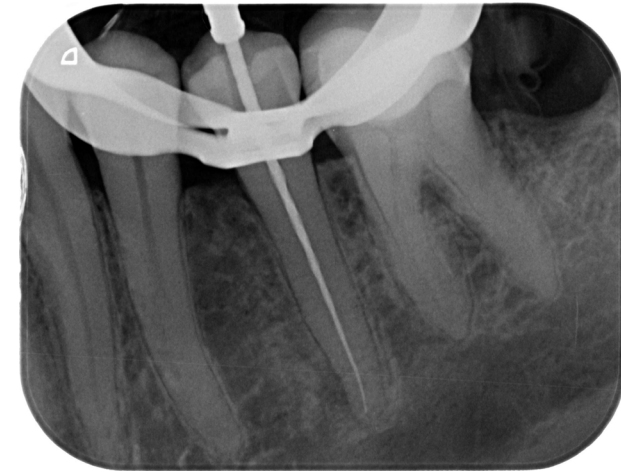Pre -op




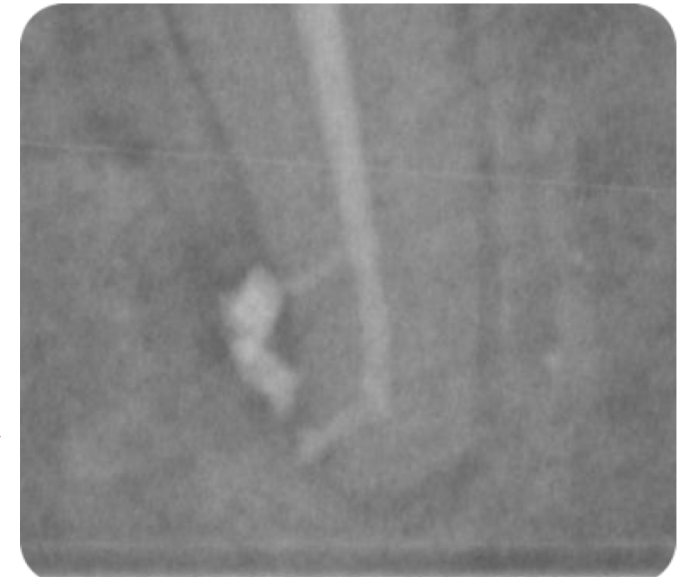
Caliform dressing at 3 weeks



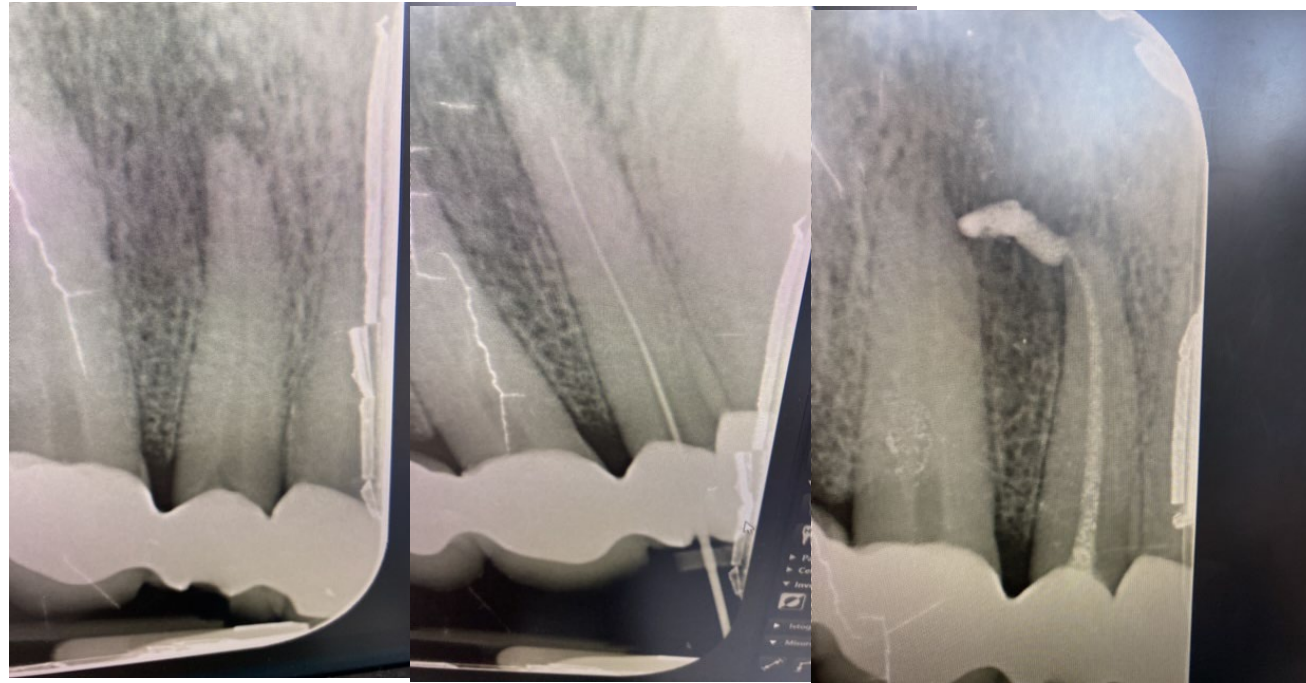
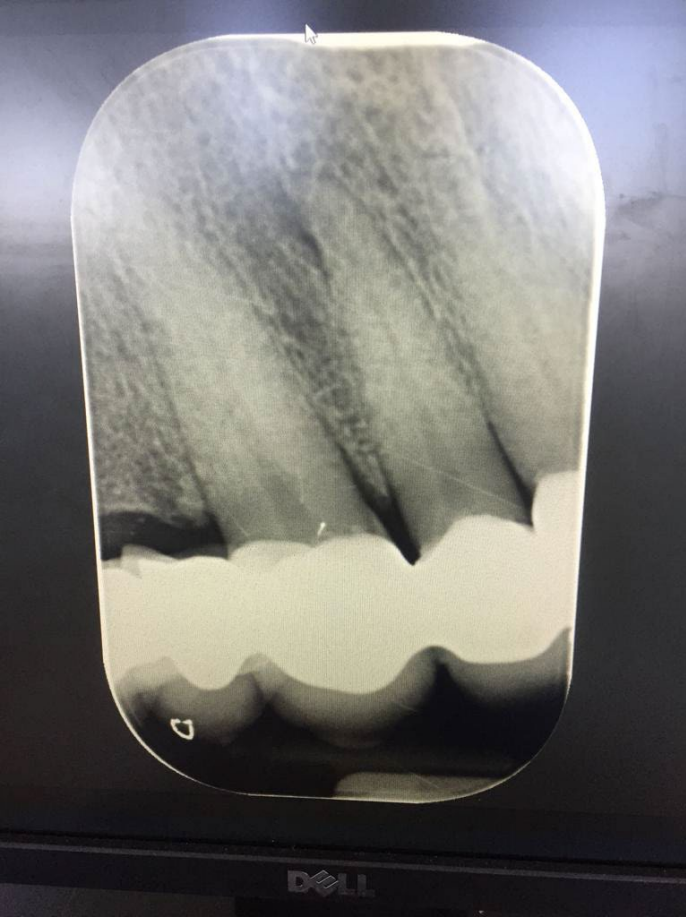Intra-op



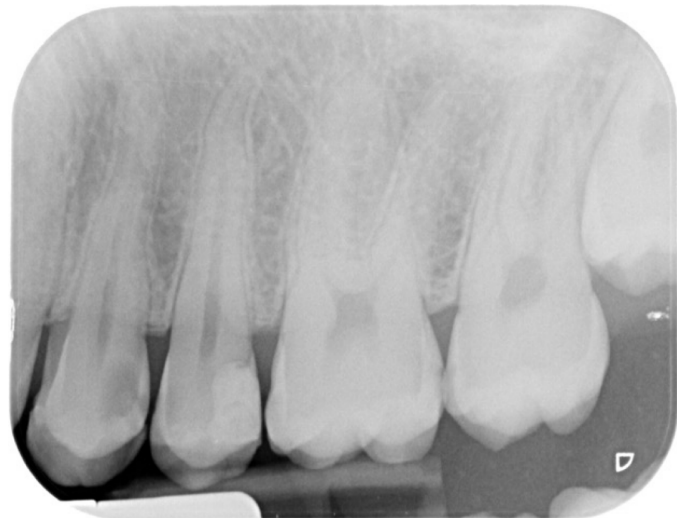Post-op



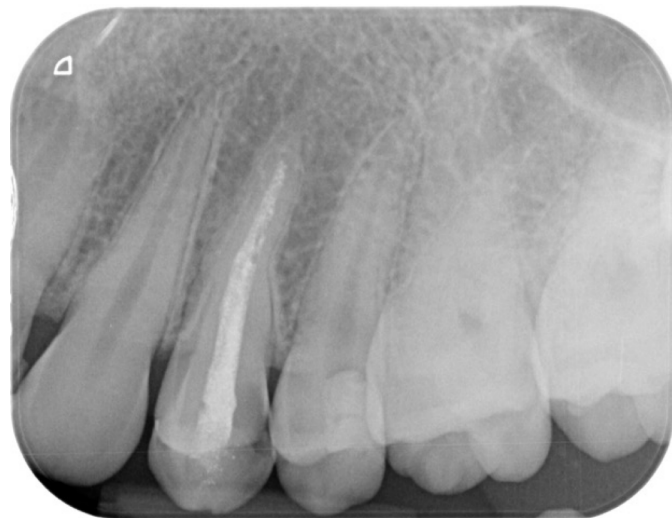MAY 2022 CALIFORM



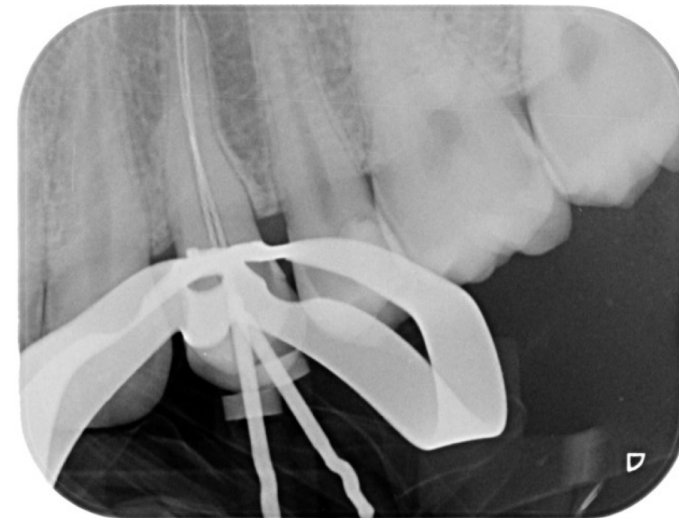
MAY 2022



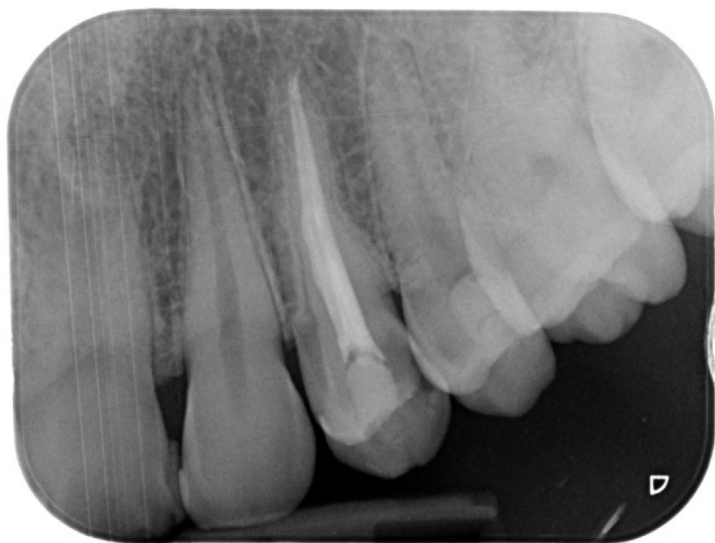Pre -op



Caliform dressing at 3 weeks

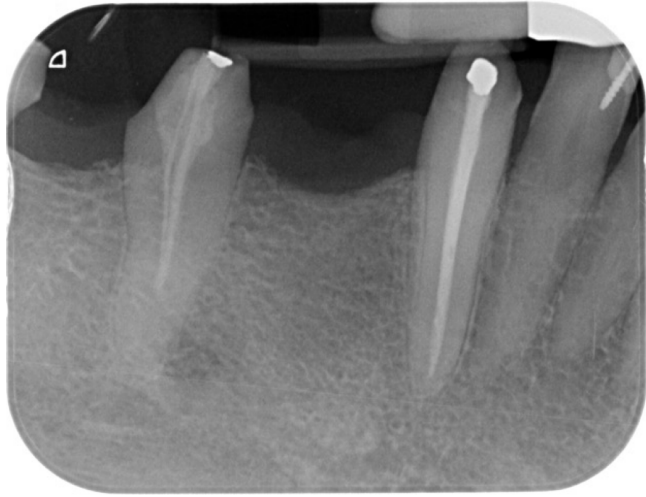

Intra -op

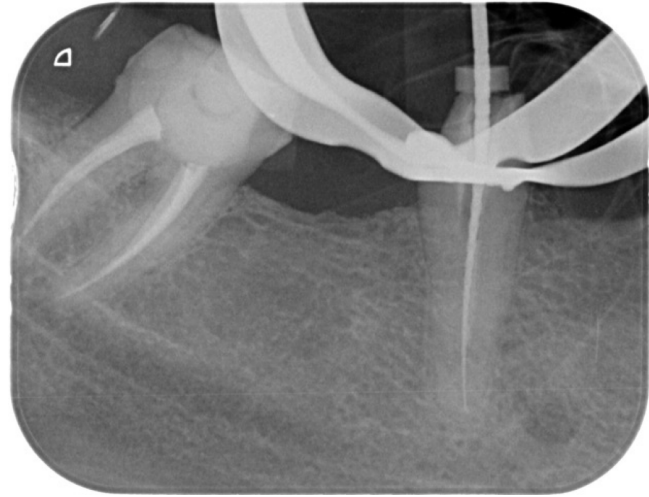


Post-op

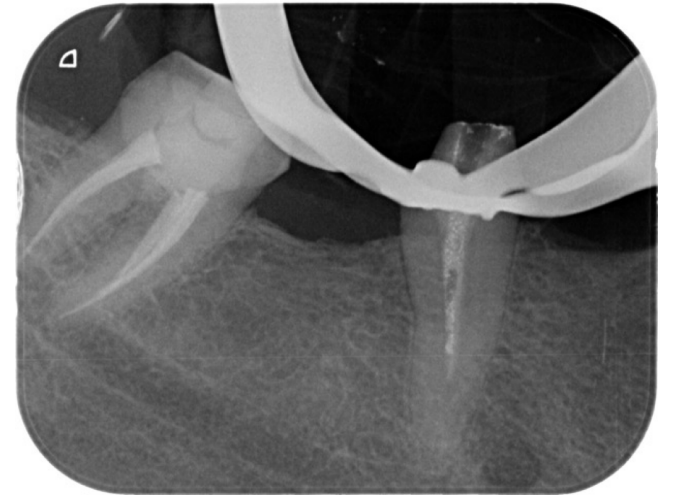
MAY 2022



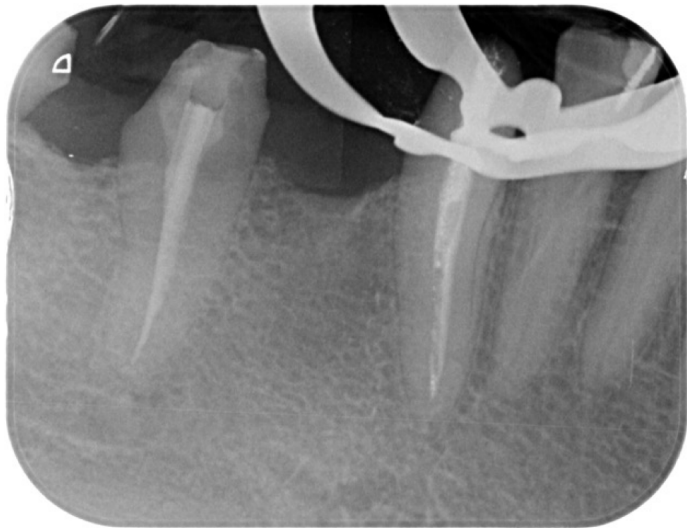
Pre -op



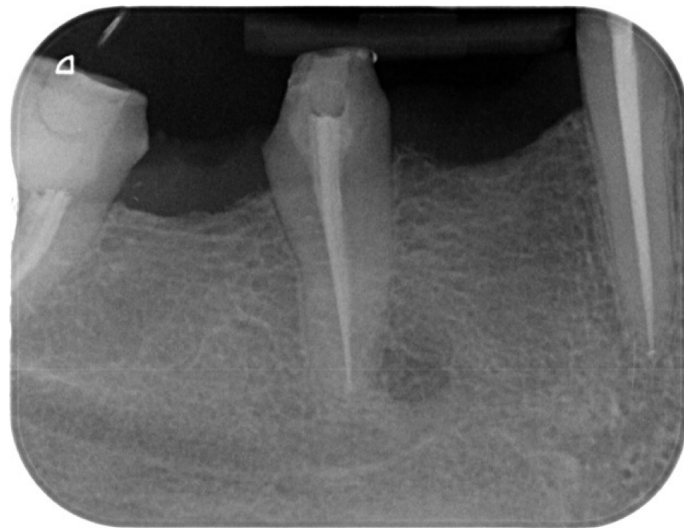
Intra -op



Caliform dressing at 3 weeks

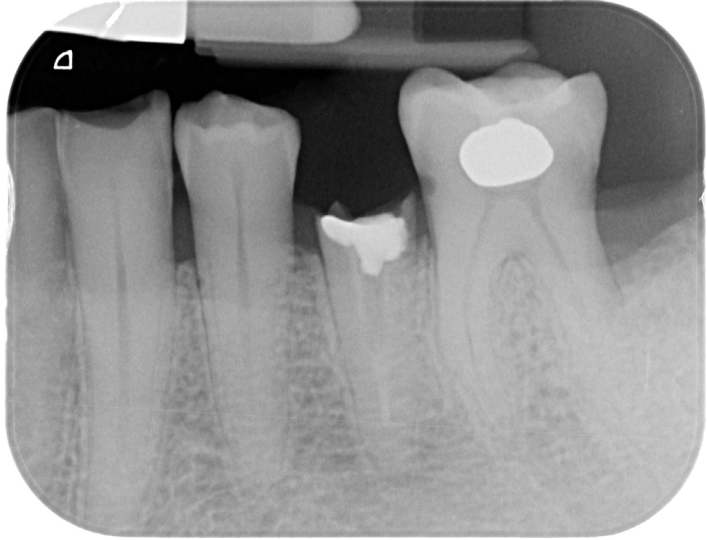

Post-op and Caliform dressing on 4.3

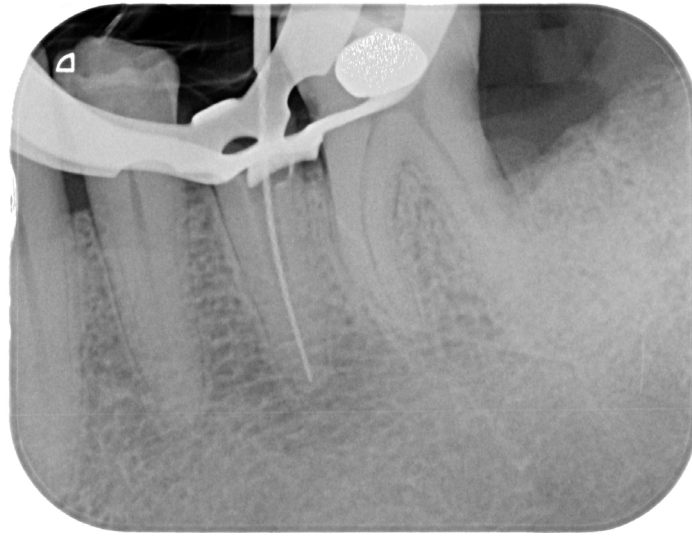


Post-op 4.3 ,4.5

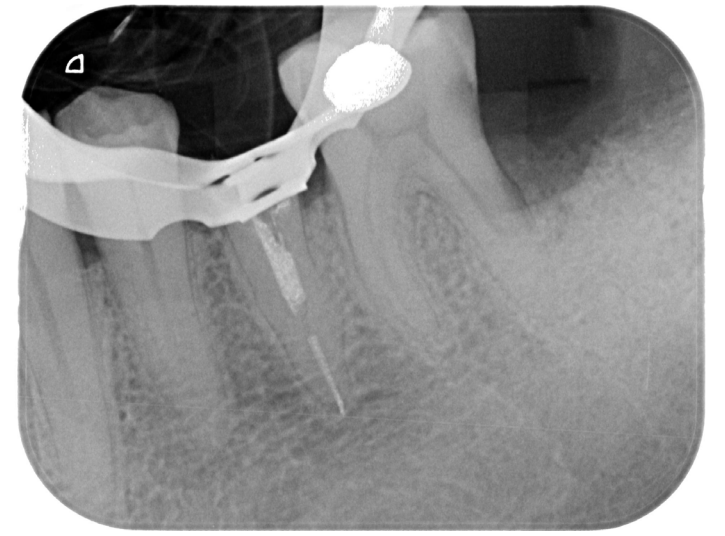
MAGGIO 2022



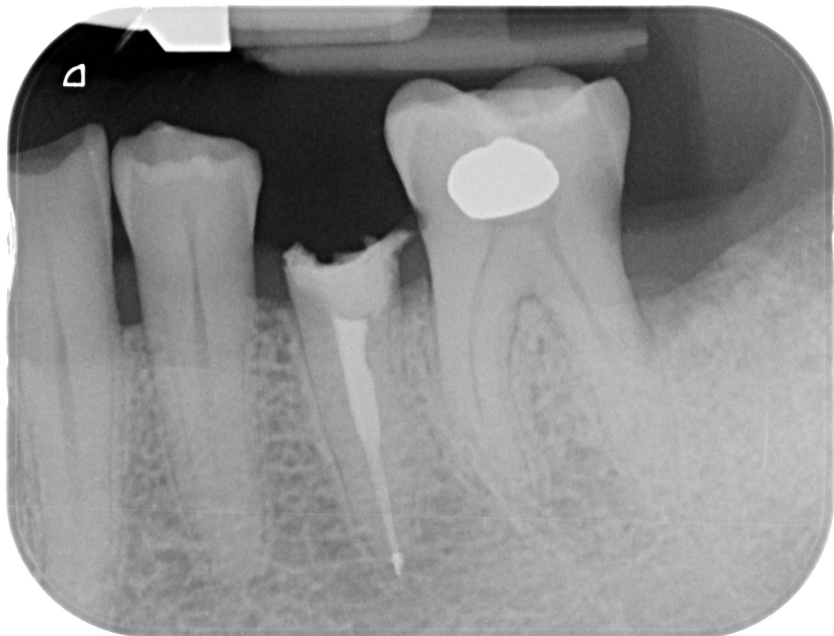Pre -op



Intra -op



Caliform dressing at 2 weeks

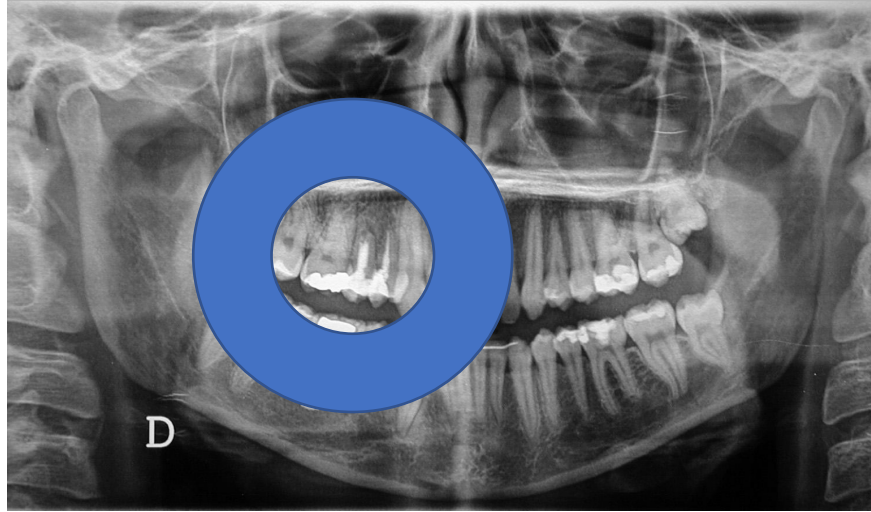


Post-op

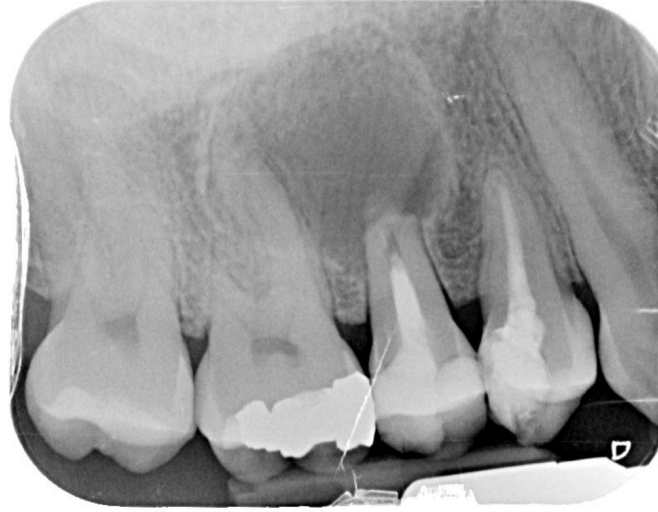Caliform as intermediary medication in the treatment of roots with periapical lesion.

- **Introduction**

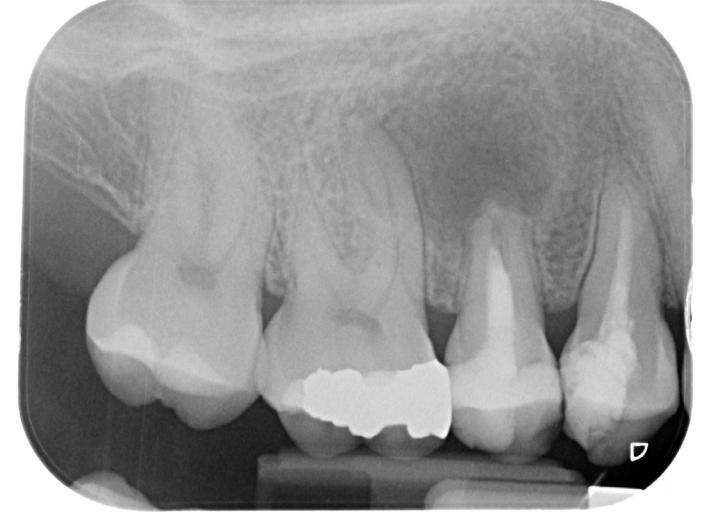- Long-term survival of endodontically treated teeth (ETT) depends on correct and well-sealing restoration and the principles of endodontic therapy, by outlining the biology of the dental pulp and periradicular tissues, the aetiology and pathophysiology of the disease processes, and the measures to diagnose, prevent, and cure the different disorders that have been established.
- It must be considered that pretty often practitioners prefer to use an intermediary medication with calcium hydroxide. This procedure is well known and accepted in daily practice and calcium hydroxide is used in order to eliminate bacteria from the canals, reduce pain of the root, wait for healing signs of periapical lesion and to postpone the final obturation when the root canal can be completely dried.
- The treatment of necrotic roots with periapical lesions can be done in a single or two appointments. When the root canal, after being instrumented, can't be dried it might be preferable to use an intermediary medication using a calcium hydroxide paste.
- The tested null hypothesis was that: there was more than 95% of long term success of necrotic ETT with a periapical lesion at the beginning of the treatment when a Caliform paste was used as intermediary medication.



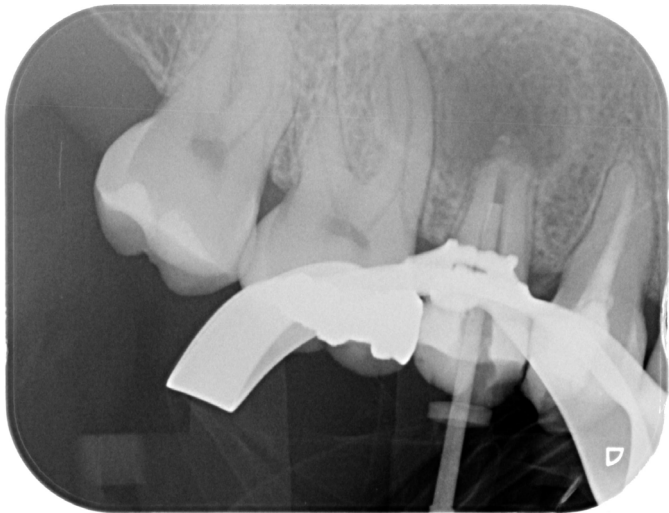
Pre-op August 2020



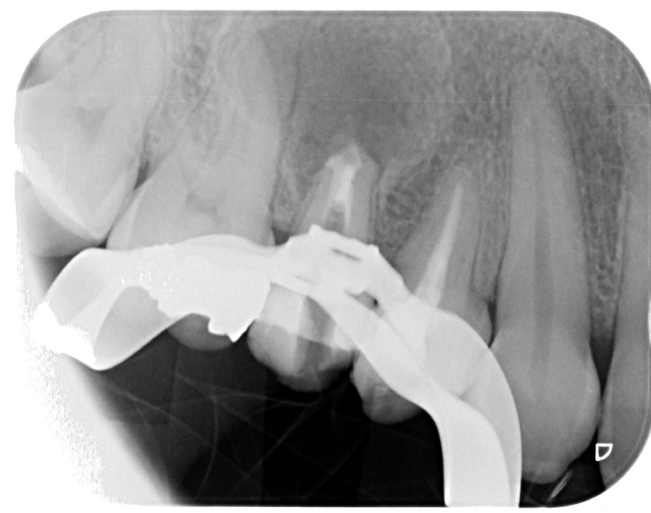
Caliform dressing



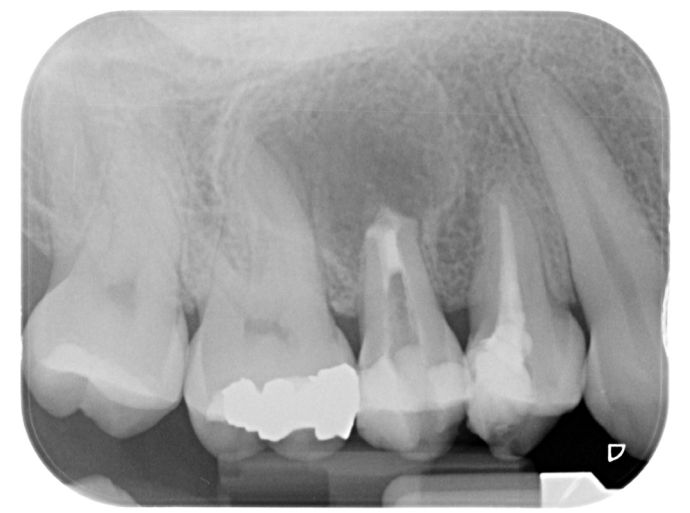Pre-op May 2022



Intra -op



Intra -op



Post-op

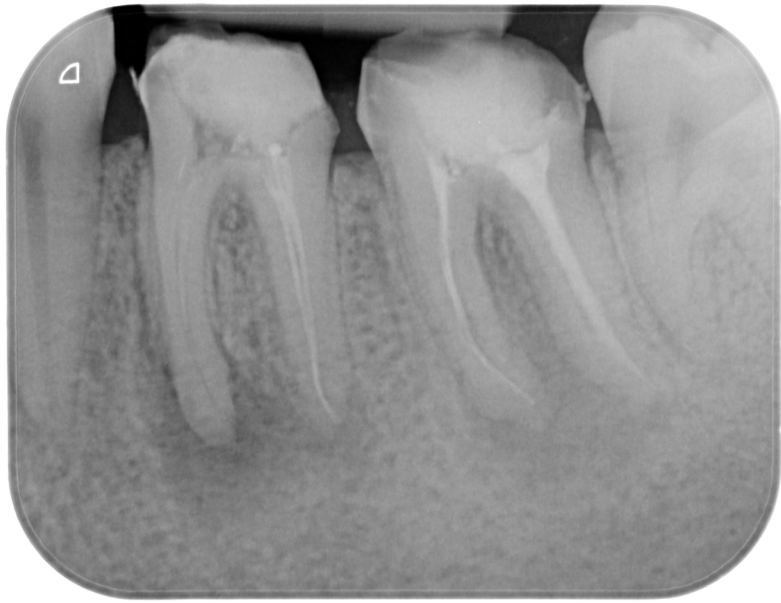Caliform as intermediary medication in the treatment of roots with periapical lesion.

- *Study Population*
- Over a three weeks period (March 2022), one expert endodontist conducted 30 endodontic treatments in 30 patients; follow-ups were done at two-three weeks and 6 months. Patients in need of endodontic therapies because of periapical lesions. Consecutive patients were selected from the authors' offices. Only primary endodontic treated teeth or nonsurgical retreatments.
- All procedures performed in this study involving human participants, were in accordance with the ethical standards of the institutional committee, and with the 1964 Helsinki declaration and its later amendments or comparable ethical standards. Informed written consent was obtained from all individual participants included in the study. Collection and analysis of the data were approved by the Ethical Committee of the University of Siena.
- Inclusion criteria were the following: age: 40 (± 6.5) years (range 18 to 65); sex: 16 F, 14 M; periodontally healthy or successfully treated patients in need of one or more endodontic treatments.
- Exclusion criteria were the following: individuals who were not yet adults (<18 years), pregnancy, disabilities, previous prosthodontic restorations of abutment teeth, deep defects (close to pulp, <1 mm distance), or pulp capping, heavy occlusal contacts, or history of bruxism, systemic disease or severe medical complications, allergic history concerning methacrylates, rampant caries, xerostomia, lack of compliance.

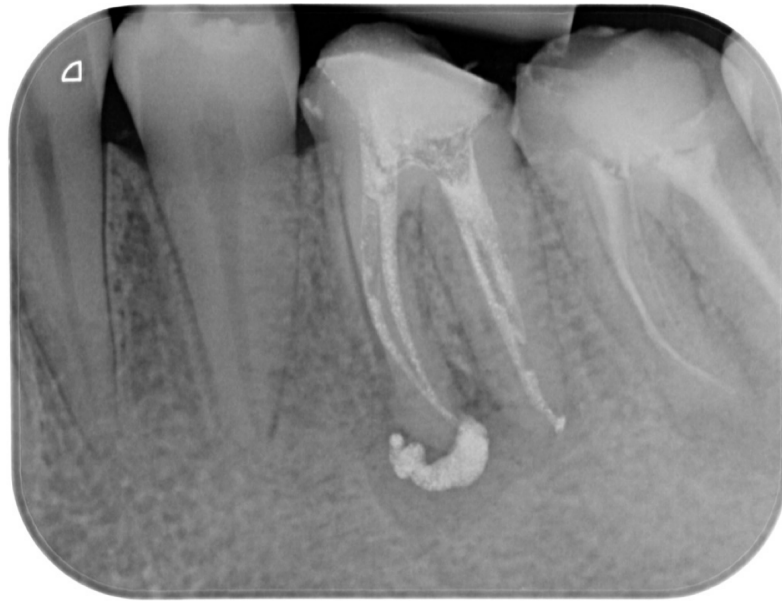Caliform as intermediary medication in the treatment of roots with periapical lesion.

- *Original Endodontic Therapy Procedure*

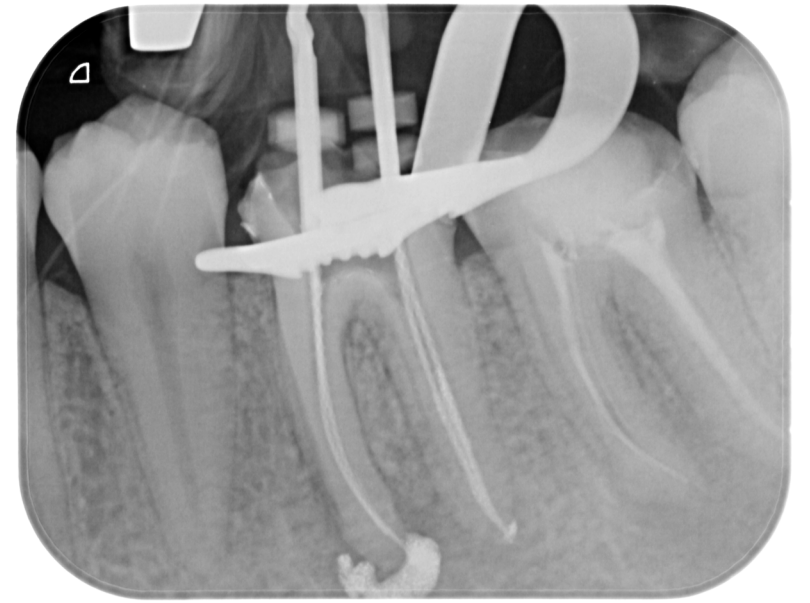- For each tooth, the following preoperative data were recorded: demographic data, tooth location, number of root canals, previous endodontic treatment, clinical signs and symptoms, vitality tests, and radiographic periapical status. Based on these findings, the preoperative condition was classified as one of the following: vital (healthy or irreversibly inflamed pulpitis), non-vital, endodontically treated, with or without periapical lesion, and symptomatic or asymptomatic.
- For each tooth, the following intra-operative data were recorded: number of treatment sessions; **inter-appointment dressing (Caliform, Oгна)**; the occurrence of procedural complications such as perforation, breakage of files and flare-up; length of canal filling (at apical level, 1 mm short or more and beyond); and temporary restoration placed. A conservative endodontic cavity (CEC) access was performed using a long shaft round diamond bur and endodontic dedicated ultrasonic tips. After straight-line access preparation was obtained, root canals were negotiated with pre-curved stainless steel K-type files (Maillefer, Bailague, Switzerland), size 0.8 or 10 ISO (International Standard Organization) to the major apical foramen. Working length was measured using an electronic apex locator (Root ZX Morita, Tokyo, Japan), established at electronic 0, and, in most cases, check with an intraoperative X-ray. Due to the long period of time that has been taken into consideration in this study, different shaping techniques and instruments have been used. From 2003 to 2013, a simultaneous technique was introduced in the clinical procedure, utilizing Ni-Ti rotary files with different tip sizes and different tapers (Mtwo, Sweden e Martina, Italy). From 2013 to 2019, a mixed technique was adopted: pre-flaring and glide path were performed to length with a nickel-titanium #10 tip size and 0.04 taper rotary file, followed by a nickel-titanium #15 tip size and 0.05 taper rotary file (Mtwo, Sweden e Martina, Italy). All canals were shaped with the M-Wire alloy rotary instruments ProTaper Next (Maillefer, Switzerland) up to a #25 tip size and a variable taper. The apical diameter was measured (apical gauging) using nickel-titanium manual K-type files, NiTi Flex (Maillefer, Bailague, Switzerland), and the shaping of the apical third was refined, where needed. Irrigation was copious and frequent using heated 5.25% sodium hypochlorite **Niclor 5 (Niclor 5, Oгна, Milan, Italy)** deposited with side-vented 30-G needles. After instrumentation, the root canals were irrigated with **17% EDTA solution (Oгна, Milan, Italy)**, for 3 min, followed again by several 1-min irrigations with heated 5.25% sodium hypochlorite solution. After being cleaned, the roots were filled with a intermediary medication paste (**Caliform, Oгна**) for 2-3 weeks. A temporary restoration was performed using zinc oxide-based cement placed on the pulp chamber floor covered by a layer of glass ionomer cement (GCem, GC Co Tokyo, Japan).
- At the second appointment (after 2-3 weeks), the patients were questioned about symptoms and it was controlled that the root canal was completely dried after removing the medicament and ready to receive the final obturation. The canals were dried with dedicated sterile paper points, filled with dedicated gutta-percha cones ProTaper Next (Maillefer, Bailague, Switzerland), and zinc oxide-based endodontic sealer (Pulp Canal Sealer, Kerr, Germany) using a continuous wave of condensation technique (75%) or a carrier-based technique (25%)(Thermafil, Dentsply, Konstanz, Germany) in roots with curve canals, depending on the root canal anatomy. A temporary restoration was performed using zinc oxide-based cement placed on the pulp chamber floor covered by a layer of glass ionomer cement (GCem, GC Co Tokyo, Japan).



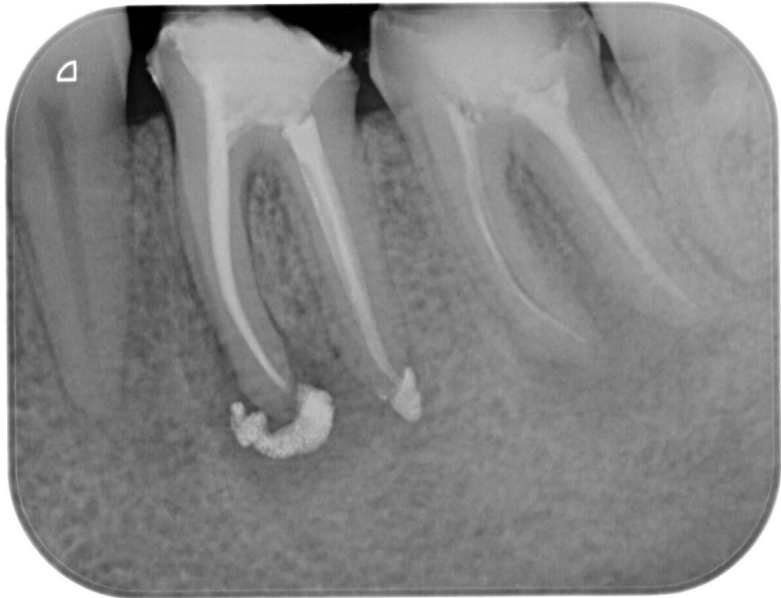Pre-op May 2022



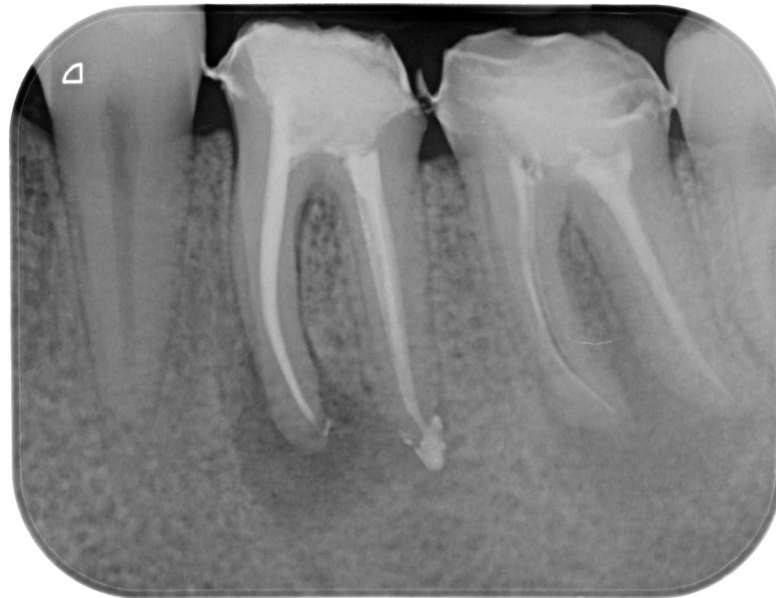Caliform dressing at 3 weeks



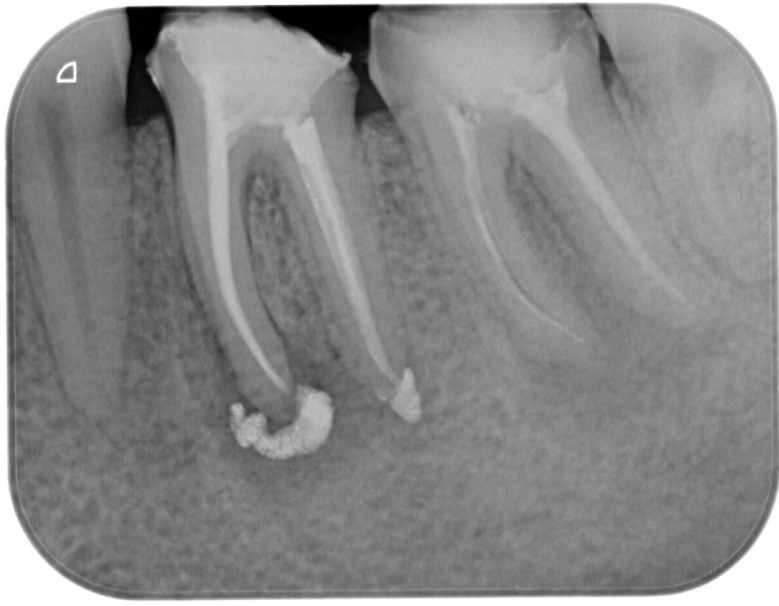Intra -op



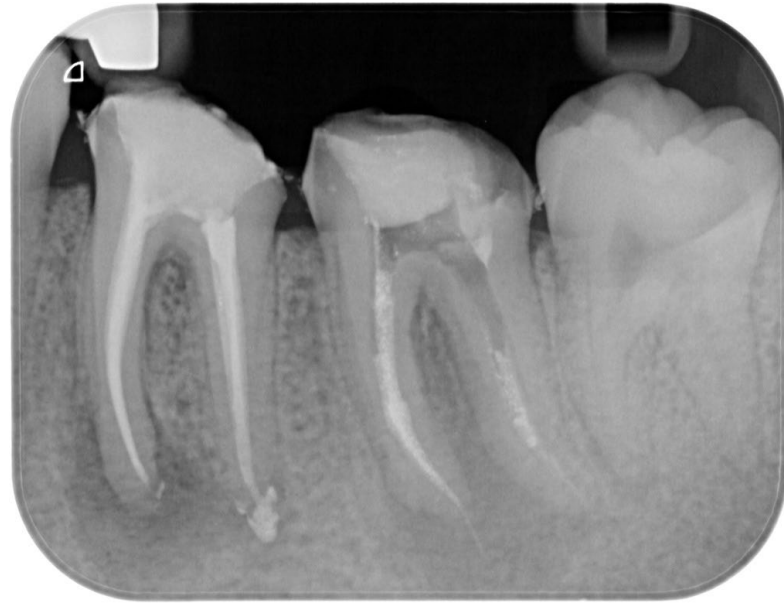Post-op



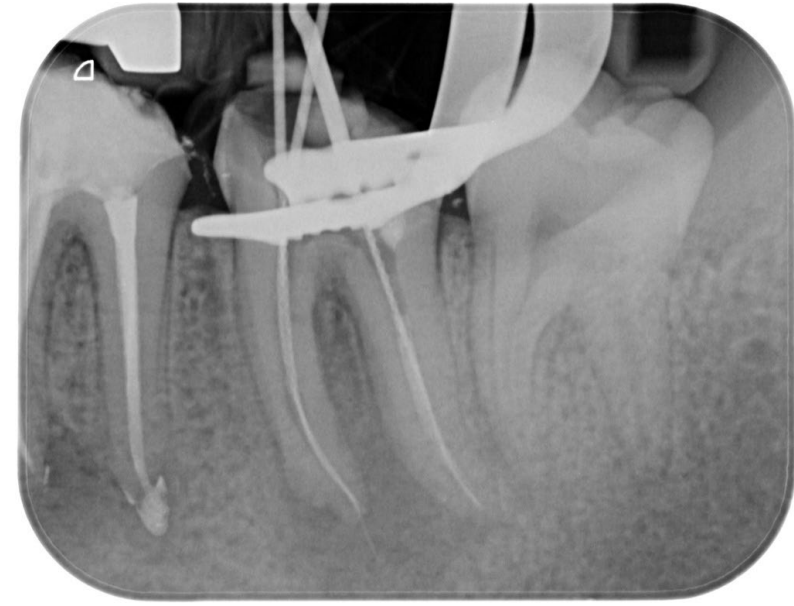Post-op at 1 month



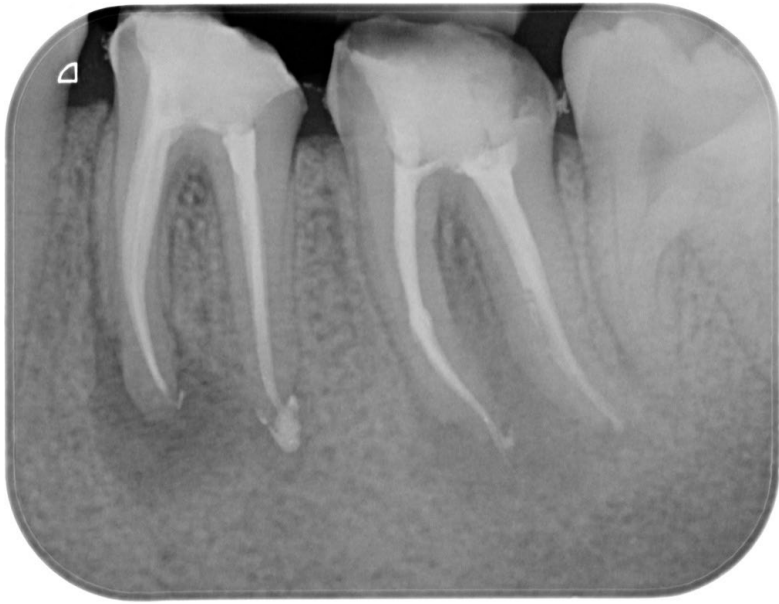Pre-op May 2022



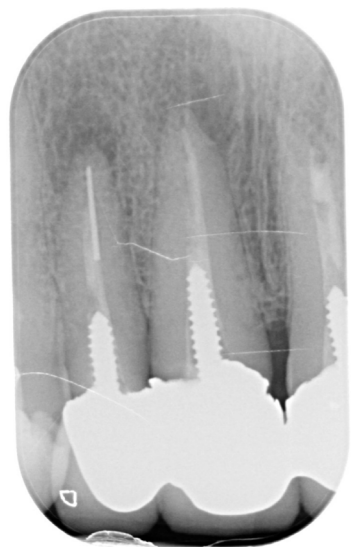Caliform dressing at 3 weeks



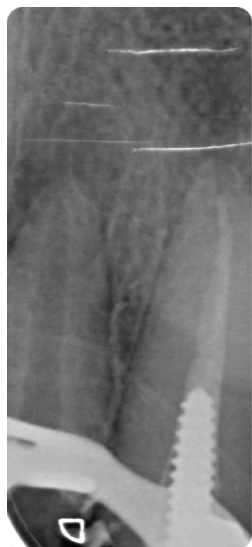Intra -op



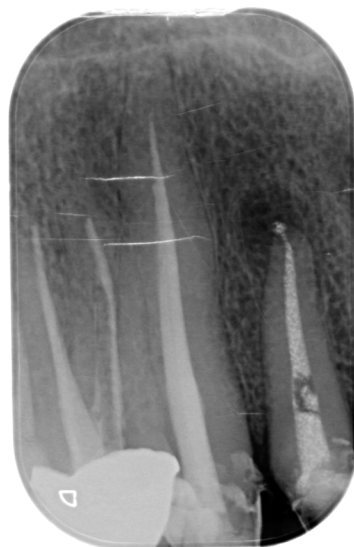Post-op



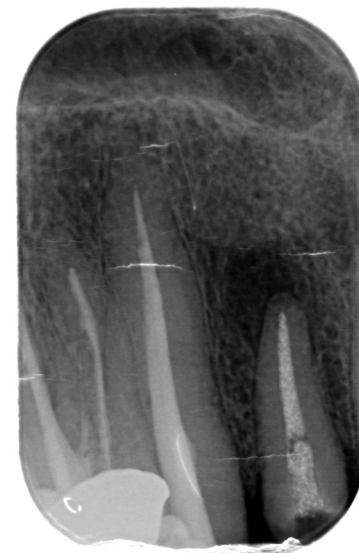Pre-op



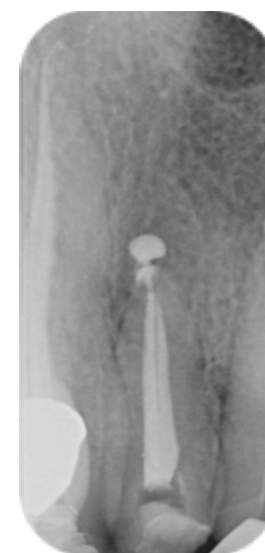Intra -op
Post
removal
and
fractured
instrument



Caliform dressing



Pre-op at 1 month

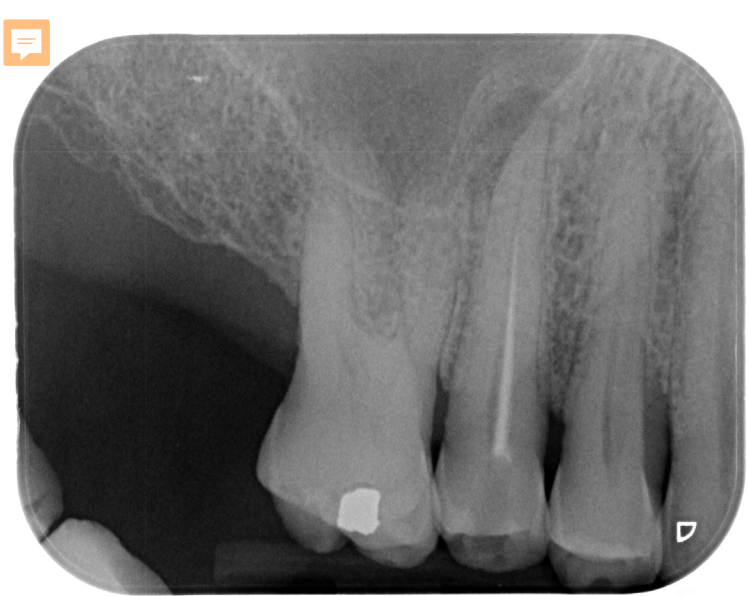

Post-op

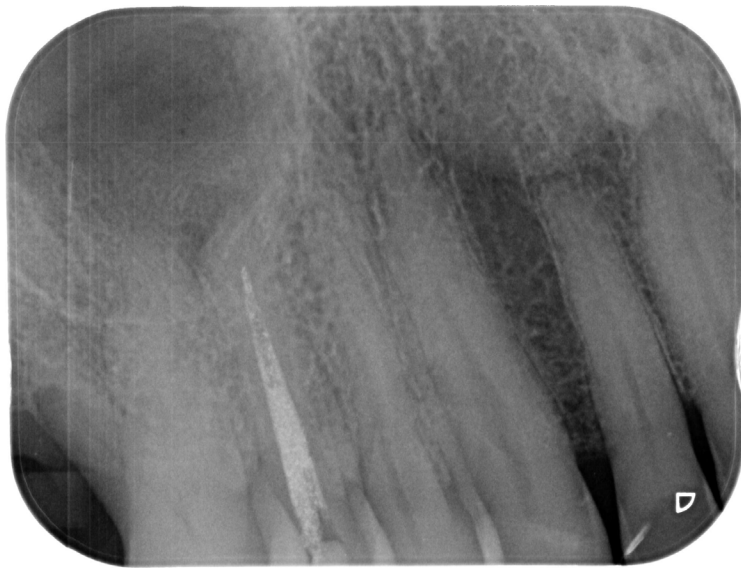Caliform as intermediary medication in the treatment of roots with periapical lesion.

- **Results**

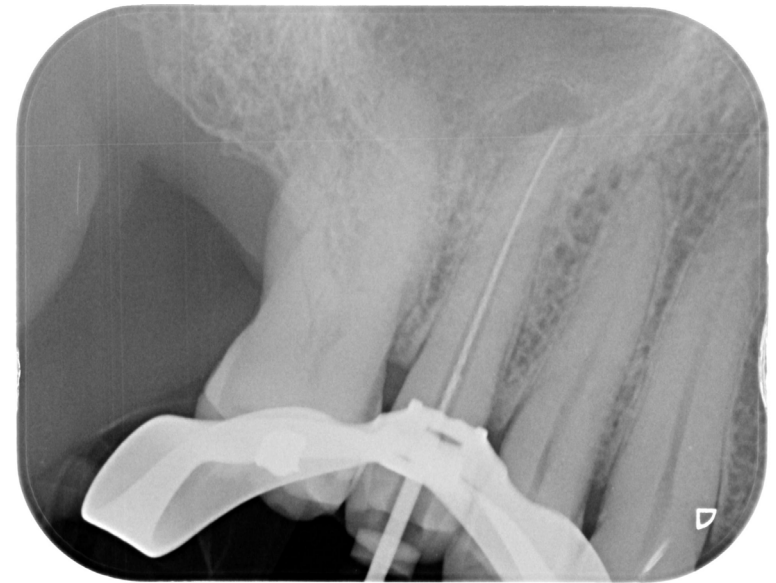
- Results showed that the 30 sample roots received a positive effect by Caliform intermediary medication.
- Patients did not present any pain at the first recall, no symptoms during the 2-3 weeks after medication, and the root canal was ready to be obturated.
- The use of calcium hydroxide paste as intermediary medication eliminated the pain of teeth and dried the root canal in two-three weeks.
- Discussion
- The long-term survival and success rates of ETT are similar and/or better than those of implants available in the literature. For that, it is mandatory to save natural teeth as many as possible. High success and survival rates of ETT are mainly related to the quality of the endodontic treatment and the restorative procedure used to save the tooth in clinical services.
- The presence of signs and symptoms—including the presence of periapical lucency— did not influence the final outcomes. In fact, in this study, only ETT showing a radiolucency visible at the baseline were selected.
- The endodontic standardized procedures used in this study were strictly followed, which could be considered another important factor that determines high-quality outcomes. At the baseline (immediately after endodontic treatment was completed) an intermediary medication with Caliform paste was used for 2-3 weeks. The Caliform paste medication resulted to be very useful in order to control pain of teeth and make dried the root canal in two three weeks. This last aspect permitted to make a final root obturation under the best clinical conditions.
- In few cases Caliform paste arrived at the periapical lesion. This observation can be due to the fact that filling necrotic teeth with periapical lesions can be more difficult than in vital teeth. The presence of an open apex can make it difficult to avoid any overfilling of the root canal.
- In some other cases, Caliform paste was partially reabsorbed but still well visible into the root canal space.
- It should note that, in this study, the clinicians performing the work were expert endodontists. The variable "operator" could be considered one of the most important factors concerning the outcomes in dentistry. Experience, knowledge, and skill of the operator can justify the high rate of success and survival for up to 15 years.



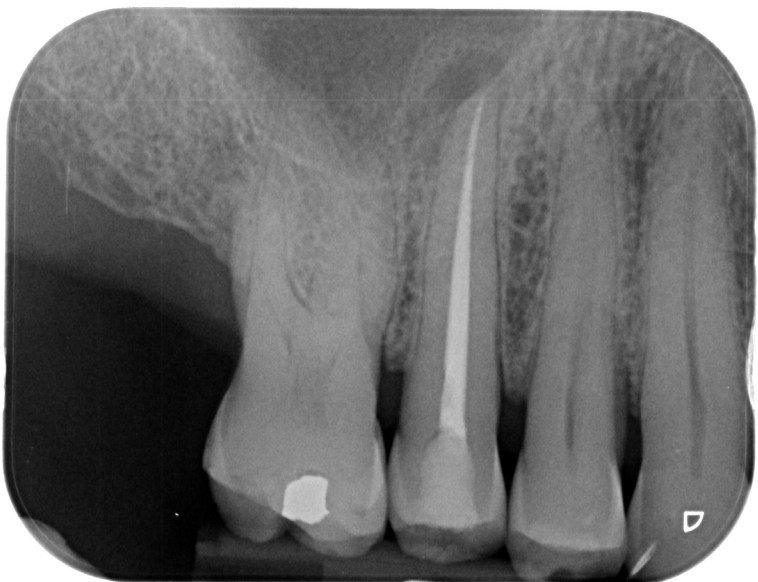Pre-op May 2022



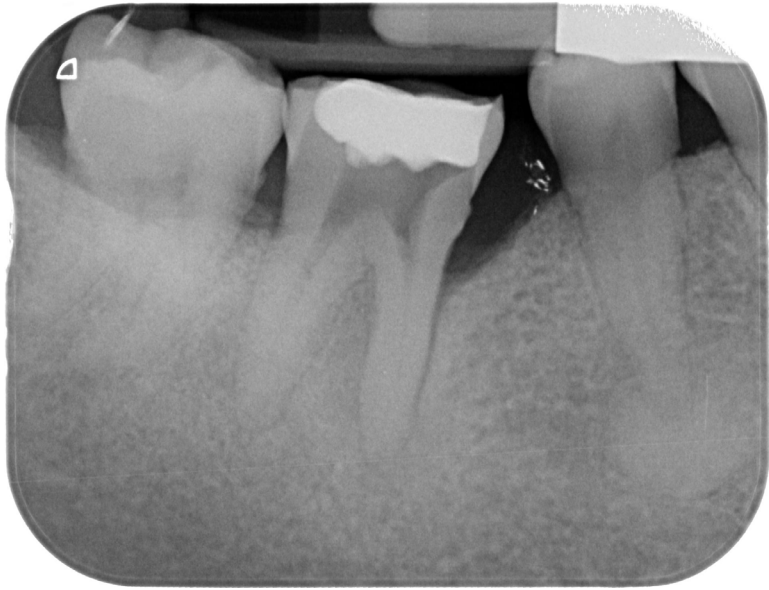Caliform dressing at 4 weeks



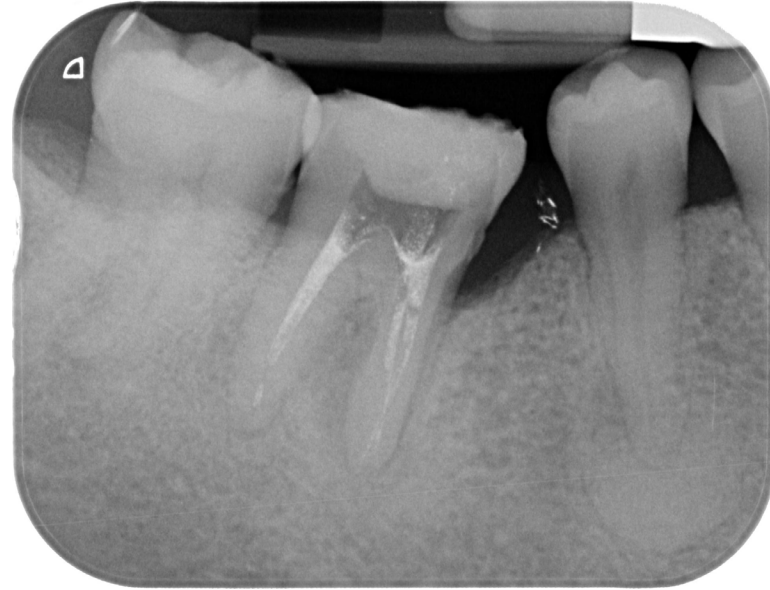Intra -op



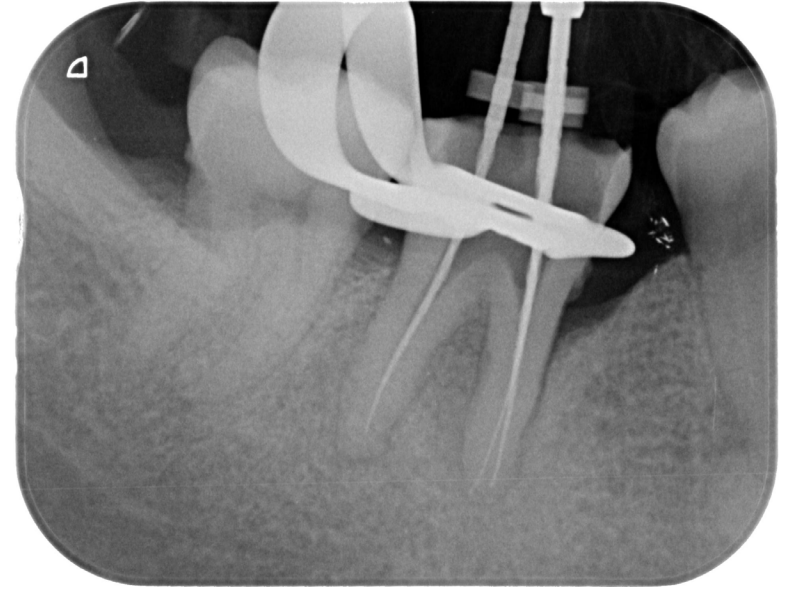Post-op



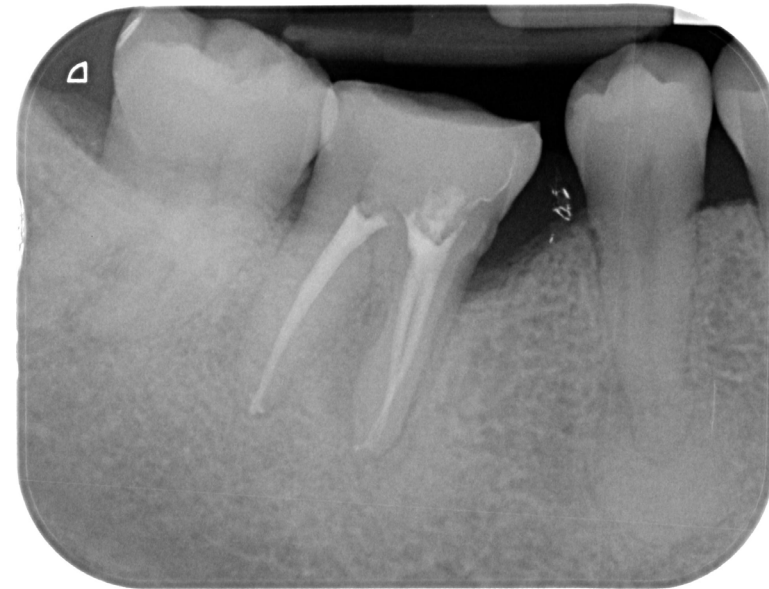Pre-op May 2022



Caliform dressing at 3 weeks



Intra -op



Post-op

Caliform as intermediary medication in the treatment of roots with periapical lesion.

- **Conclusions**


- The use of Caliform intermediary medication can improve quality life of the patients. The presence of a periapical lesion at the baseline does not decrease the quality of the outcome. The use of Caliform paste was successful to eliminated pain of the roots, and permit to make a proper root canal obturation having the canal completely dried after two-three weeks.

Prof. Marco Ferrari, MD, DMD, Ph D

Dean

School of Dental Medicine

University of Siena

A handwritten signature in black ink, reading "Marco Ferrari". The signature is written in a cursive, flowing style with a large, prominent 'M' and 'F'.